

Fatal Envenoming by the Snake *Atractaspis* Newly Recorded in the Central Region of Saudi Arabia

Mohamed K. Al-Sadoon and Nasr M. Abdo

*Department of Zoology, College of Science, King Saud University,
P.O. Box 2455, Riyadh 11451, Saudi Arabia*

(Received 27 March 1989; accepted for publication 30 October 1990)

Abstract. A fatal case of snakebite led to the first recognition of the oasis burrowing asp, *Atractaspis microlepidota engaddensis* Hass, 1950:52 in the Central Region of Saudi Arabia. Identification, measurements of this snake, the recent distribution and classification of the genus and its species in Arabia are provided. Symptoms of envenoming in relation to the reported venom composition and its mode of action are also discussed.

Introduction

The ophidian fauna of Arabia appears to be very rich in venomous, mildly venomous and innocuous species. There are at least fifty one species of which nine are venomous sea snakes, nine venomous terrestrial species and the rest are innocuous [1-7].

Snakebite in Arabia has been poorly documented; in addition to sea snakes there are six species that can cause fatal bites [8]. It has been noted that characterization of the venoms of Viperidae as "haemotoxic" and the Elapidae as "neurotoxic" is inaccurate and out of date [9]. Regardless of taxonomy, venoms which have a high proportion of neurotoxic and cardiotoxic fractions are more likely to kill quickly. The case reported here ended fatally within one hour – a relatively swift death in snakebite terms. The species involved which has been identified as *Atractaspis microlepidota engaddensis* has long been considered a viper, but is now placed in a separate family, Atractaspididae [5,9]. The venom composition and its mode of action have been discussed [9-12]. The medical importance of this species results from its wide distribution (in western, southern and now central Arabia), the potency of its venom and the lack of any specific antivenom (Hospital registration sources).

Materials and Methods

The Case Report

The fatal case occurred on the 3rd, of May 1987. While moving inside her home in Dirriyah, on the boundaries of Riyadh, Central Region of Saudi Arabia, a two year old female child was bitten on the dorsum of her right foot by a snake that had entered their living room. The snake was killed on the spot. She was rushed to a nearby health facility (Dirriyah Health Centre) by her parents. The estimated time of the bite was 2130 hr and time of arrival at the clinic was 2145 hr. On examination by the doctor there was only one fang mark, but no swelling was observed. She did not vomit. Her general condition was recorded serious. She was semi-conscious and appeared cyanosed. Her pupils were dilated and reacted sluggishly to light. She was given 100% O₂ and 5 cc polyvalent antivenom intra-muscularly (Pasteur anti Bitis-Echis-Naja Venom Serum). Then she was quickly transferred by ambulance to the nearest hospital in Riyadh, King Khalid University Hospital. She was reported to be restless, however, halfway between the Health Centre and K.K.U. Hospital she stopped moving, and external cardiac massage was started by the escort nurse. Upon arrival at 2200 hr, she was received in the Main Accidents and Emergency Dept. and was found to be unconscious. She was intubated and transferred to the Paediatrics Emergency Room. On examination there was no blistering, swelling or discolouration at the site of bite. She was found to be in cardio-respiratory arrest with dilated pupils. Active resuscitation was carried out by the CPR-Team and the medical staff. Resuscitation was continued with anti-shock treatment including Na bicarbonate (1 ampoule), 1/10 000 (0.01%) adrenaline (3 cc), 10% Ca gluconate (5 cc) and fresh frozen plasma (55 cc). She did not respond and resuscitation was stopped at 2215 hr.

The Snake

The snake responsible was preserved in formalin and sent from K.K.U Hospital to the College of Pharmacy and thence to the College of Science, Zoology Department of the King Saud University at Riyadh. It was identified as a burrowing asp, *Atractaspis microlepidota engaddensis* (Table 1). Common names for this species include, mole viper, false viper, burrowing adder, side-stabbing snake, stilleto snake [13,14], and burrowing asp [9]. This species has not previously been reported before anywhere in the Central Region. However, other examples of this species are known from northern and western Arabia [4,5,15].

Discussion

The snake responsible for this fatal case was a large adult, 752 mm long (Table 1). The total length of other specimens from the Near and Middle East fell between 457.2-635 mm [15], and 295-894 mm with an average of 576 mm [5]. The habits of this

Table 1. Identification characteristics of the snake here identified as *Atractaspis microlepidota engaddensis*

Character	Description
Total length	752 mm
Tail length	64 mm
Sex	Female adult
Dorsal colour	Shining Black
Belly	Bluish black
Scales	Small and very smooth
Head	Very small, not distinct from neck, triangular in shape
Crown plates	The usual 9 plates, symmetrical and large, the frontal is very broad, Parietals large
Nasals	Nasals split at lower half
Ventrals	279 scales
Anal plate	Entire
Subcaudals	39 single scales, the last one transformed into a spine
Dorsal rows at midbody	26 Non-oblique rows

species have been reported [2,15,16; pp. 403-435]. It appears to be a nocturnal hunter which lives underground and comes out of its burrows only after rains. Although, the name mole viper implies that this species is a true viper, there is much controversy over its classification. It was long considered to be a member of the family Viperidae [17; pp. 309-325]. Others demonstrated that it is not a member of that family [18]. Most taxonomists then placed the taxon in the subfamily Aparallactinae, of the family Colubridae [19]. Then the snakes of the genus *Atractaspis* were placed in the family Atractaspididae, which is now generally accepted [20]. The general and cranial anatomy, including the maxillary fang mechanism, the head musculature and fine structure of the venom gland, support the latter argument. Thus the name Atractaspididae is chosen for the new family [9,12].

The genus comprises fifteen species, one of which is found in Sinai, Palestine and the Arabian Peninsula, [19,21; p. 15], along the western montane periphery through Yemen, and eastward to Dhofar, with evidence of a population near Hail [5], and this present record from the vicinity of Riyadh. There is some confusion concerning the taxonomy of the two subspecies reported in Arabia [2]. Fig. 1 shows the combined distribution of *A. m. andersonii* and *A. m. engaddensis* in Arabia [5,22]. The same distribution has been reported [15], showing representatives of *A. m. engaddensis* as occurring northwards to Israel and *A. m. andersonii* in the southern part of the Arabian Peninsula. *A. m. andersonii* is recognized locally (South Arabia) by the name "Al-Aswad" (the black one) [2,23]. It has caused several bites and fatalities amongst the Zahran, Shahrhan and Ghamid peoples [2].

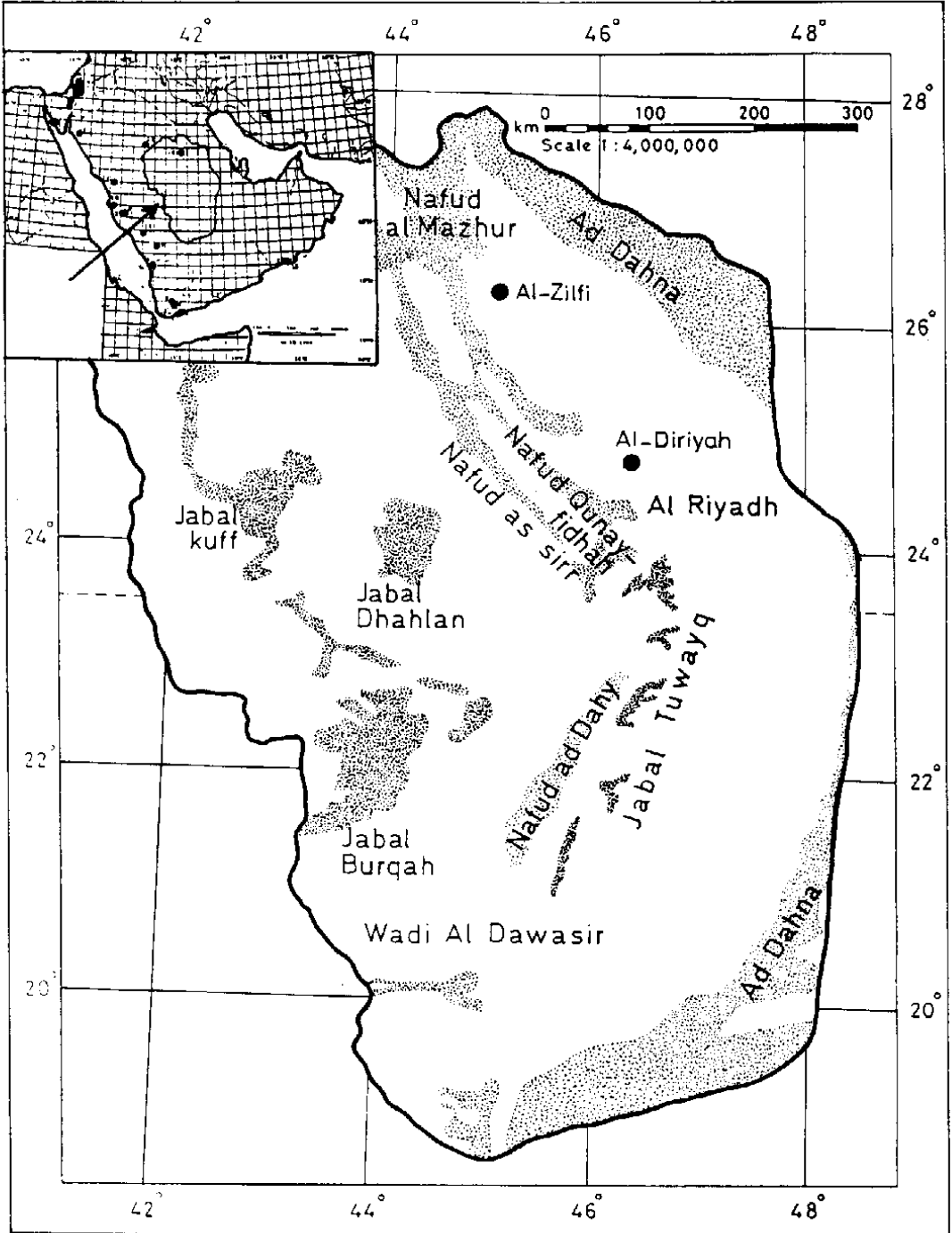


Fig. 1. Distribution of the burrowing asp. *A.m. engaddensis* in the Central Region of Saudi Arabia, Inset: the records by J. Gasperetti (including the sub-species *A.m. andersonii*) in the Arabian Peninsula (1988). Map was redrawn from the original (Property of the Ministry of Petroleum and Mineral Resources, Kingdom of Saudi Arabia).

It is interesting to note how snakes of this genus bite. Their movable fangs are long for so small a snake and they can drop one or both fangs below and away from its lower jaw and bite with a backward movement of the head rather than by a forward thrust [2,4]. These burrowing asps can bite without opening the mouth [9]. Strikes of all *Atractaspis* species observed are characterized by jerky sideways-downward-backward movements of the head with only one, slightly erected fang protruding lateral to the lower jaw. "Irritated" snakes are sometimes seen stabbing repeatedly in a fast left-right sequence, with small drops of venom left as evidence, on each side [9]. An explanation for the fables among villagers in southern Arabia that these snakes can inflict instantaneous death by biting with any part of their bodies has been reported [2]. Examination of the mouth of the snake responsible for this case revealed only one fang which was 6 mm long in comparison with the head size (18 × 9 mm). The other fang might have been lost either in the event of stabbing the victim or when it was killed by the victim's family.

Research on the venom composition and its mode of action has presented difficulties to researchers due to the scarcity of the snake and inability to obtain the venom by the conventional methods [3,10,24]. The intravenous (I.V.) LD₅₀ of *A. m. engaddensis* whole venom was 1.5 µg per mouse or 0.06-0.075 µg/g body weight [9,12].

The venom of *A. m. engaddensis* has a very rapid action and death results from cardiotoxic effects, though it has long been considered to be neurotoxic without stimulatory contractive effects on skeletal muscles [12]. It has been found that *A. m. engaddensis* venom with its sarafotoxins caused severe coronary vasoconstriction and atrio-ventricular block [25,26,27]. Because of the circumstances surrounding the bite, the cause of death in the present case was not established. It is likely that a large venom to mass ratio was present. With the rapid onset of obtundation proceeding to death within one hour for the bite, it is presumed that the cardiovascular and/or neurological systems were compromised. This would be in keeping with the known experimental and clinical data on the action of the venom [4,24,25,26,28; pp. 463-527]. Although, anaphylaxis to the antivenom is also a possibility, the patient was clearly already desperately ill even before the antivenom was injected. An anaphylactoid response to the venom of this species has also been described [10].

The reported actions of the venom are both local and systemic. Numbness, oedema and necrosis are the local effects. Systemic effects include nausea, abdominal pain, sweating, profuse salivation, loss of ocular accommodation, loss of consciousness, liver damage, haemorrhage, dyspnoea, hypertension, hypoxia, hypercapnia and disorders of cardiac activity [9,10,11,25,27,29; p. 331, 30,31,32]. Death ensues from respiratory paralysis, cardiotoxicity [10,25,26,27,33], and venom induced anaphylaxis [10].

The venom of *Atractaspis* is unique in composition, contributing to its many differences from other snakes and possibly a strong point in the characterization of this genus to belong to a separate family, Atractaspididae [9]. It would be interesting to study the venom of the snake *A. m. andersonii* found in the southern and western regions of Arabia and compare it with that of *A. m. engaddensis* present in the central and northern regions with the aim of finding taxonomic or phylogenetic determinants in the venoms. The use of venom properties as tools for taxonomic and phylogenetic studies of *Cerastes cerastes* snakes has been reported [34].

Antisera for *Atractaspis* venom have been difficult to produce and are lacking in Saudi Arabia [Ismail, M. personal communications]. Records of snakebite cases in the Central Region are important to document and need further attention [Hospital registration sources]. Treatment in cases of bites consists of symptomatic treatment and the administration of non-specific polyvalent antivenom is of questionable value. This would call for an effort to produce potent antivenoms in Saudi Arabia against *A. m. engaddensis* and other snakes of medical importance.

Acknowledgements. Our deep thanks are due to Dr.F.Z. Al-Faleh, Dean Faculty of Medicine, and King Khalid University Hospital supervisor for the access of medical data and information, Mr. John Gasperetti of the California Academy of Sciences (Now a member of the Saudi Meteorology and Environment Conservation Corporation) for his help in taxonomic classification and to Prof. M. Ismail of the College of Pharmacy for critically reading the manuscript.

References

- [1] Mandaville, J.P. Jr. "The Hooded Malpolon, *Malpolon moilensis* Reuss, and Notes on Other Snakes of Northeastern Arabia." *J. Bombay Nat. Hist. Soc.*, 64, No. 1 (1967), 115-117.
- [2] Gasperetti, J. "A Preliminary Sketch of the Snakes of Arabian Peninsula." *J. Saudi Nat. Hist. Soc.*, 12 (1974), iv, 72.
- [3] Gasperetti, J., "Walterinnesia aegyptia Lataste, a Rare Black Snake." *J. Saudi Nat. Hist. Soc.*, 18 (1976), 13-15.
- [4] Gasperetti, J. "Snakes in Arabia." *J. Saudi Nat. Hist. Soc.*, 19 (1977), 3-16.
- [5] Gasperetti, J. "Snakes of Arabia." *Fauna of Saudi Arabia*, 9 (1988;), 169-450.
- [6] Leviton, A.E. "A New Lytorhynchid Snake." *J. Saudi Nat. Hist. Soc.*, 19 (1977), 16-25.
- [7] Al-Sadoon, M.K. "Survey of the Reptilian Fauna of the Kingdom of Saudi Arabia; I. The Snake Fauna of the Central Region." *J. King Saud Univ.*, 1, Science (1,2) (1989), 53-69.
- [8] Tilbury, C.R.; Madkour, M.M.; Saltissi, D. and Suleiman, M. "Acute Renal Failure Following the Bite of Burton's Carpet Viper, *Echis coloratus* Gunter in Saudi Arabia: Case Report and Review." *Saudi Med. J.*, 8, No. 1 (1987), 87-95.
- [9] Kochva, E.; Viljoen, C.C. and Botes, D.P. "A New Type of Toxin in the Venom of Snakes of the Genus *Atractaspis* (Atractaspidinae)." *Toxicon*, 20, No. 3 (1982), 581-592.

- [10] Chajek, T.; Rubinger, D. Alkan, M.; Melmed, R.M. and Gunders, A.E. "Anaphylactoid Reaction and Tissue Damage Following Bite by *Atractaspis engaddensis*." *Trans., R. Soc. Trop. Med. Hyg.*, 68 (1974), 333-337.
- [11] Mann, G. and Gunders, A.E. "Epidemiology of Snakebites in Israel." *Family Physician*, 7 (1977), 83.
- [12] Weiser, E.; Wollberg, Z.; Kochva, E. and Lee, S.Y. "Cardiotoxic Effects of the Venom of the Burrowing asp, *Atractaspis engaddensis* (Atractaspididae, Ophidia)." *Toxicon*, 22, No. 5 (1984), 767-774.
- [13] Branch, W.R. "The Venomous Snakes of Southern Africa. Part I. Introduction and Viperidae." *The Snake*, 9 (1978), 67-74.
- [14] Branch, W.R. "Venom Yields from Three Species of Sidebiting Snakes (genus *Atractaspis*: colubridae)." *Toxicon*, 19 (1981), 271-277.
- [15] Bureau of Medicine and Surgery, "*Poisonous Snakes of the World*." (A manual for use by U.S. Amphibious Forces). NAVMED P-5099. Washington, D.C.: United States Government Printing Office, 1979.
- [16] Broadley, D.G., "The Venomous Snakes of Central and South Africa." In: Bucherl, W.; Buckley, E.E. and Deulofeu, V. (eds), *Venomous Animals and Their Venoms* (Vol. 1). New York and London: Academic Press, 1968.
- [17] Klemmer, K. "Classification and Distribution of European, North African, and North and West Asiatic Venomous Snakes." In: Bucherl, W.; Buckley, E.E. and Deulofeu, V. (eds), *Venomous Animals and Their Venoms* (Vol. 1). New York and London: Academic press, 1968.
- [18] Underwood, G. "A Contribution to the Classification of Snakes." *B.M. (N.H.) Publication*, No. 653 (1967), X, 179.
- [19] Tilbury, C.R. and Branch, W.R. "Observations on the Bite of the Southern Burrowing Asp (*Atractaspis bibronii*) in Natal." *S. Afr. Med. J.*, 75 (1989), 327-331.
- [20] Kochva, E. "The Origin of Snakes and Evolution of the Venom Apparatus." *Toxicon*, 25, No. 1 (1987), 65-106.
- [21] Underwood, G. "Classification and Distribution of Venomous Snakes in the World." In: Lee, C.Y. (ed), *Snake Venoms*. New York: Springer-Verlag, 1979.
- [22] Boulenger, G.A. "Description of Three New Snakes Discovered in South Arabia by Mr. G.W. Bury." *The Annals and Magazine of Natural History*, Series 7, Vol. 16 (1905), 178-180.
- [23] Corkill, N.L. and Cochrane, J.A. "The Snakes of the Arabian Peninsula and Socotra." *J. Bombay Nat. Hist. Soc.*, 62, No. 3 (1965), 474-506.
- [24] Corkill, N.L.; Ionides, C.J.P. and Pitman, C.R.S. "Biting and Poisoning by the Mole Vipers of the Genus *Atractaspis*." *Trans. R. Soc. Trop. Med. Hyg.* 53 (1959), 95-105.
- [25] Alkan, M.L. and Sukenik, S., "Atrioventricular Block in a Case of Snake Bite Inflicted by *Atractaspis engaddensis*." *Trans. R. Soc. Trop. Med. Hyg.*, 69 (1974), 166-183.
- [26] Lee, S.Y.; Lee, C.Y.; Chen, Y.M. and Kochva, E. "Coronary Vasospasm as the Primary Cause of Death Due to the Venom of the Burrowing Asp, *Atractaspis engaddensis*." *Toxicon*, 24, No. 3 (1986), 285-291.
- [27] Wollberg, Z.; Shabo-Shina, R.; Intrator, N.; Bdolah, A.; Kochva, E.; Shavit, G.; Oron, Y.; Vidne, B.A. and Gitter, S. "A Novel Cardiotoxic Polypeptide from the Venom of *Atractaspis engaddensis* (Burrowing Asp): Cardiac Effects in Mice and Isolated Rat and Human Heart Preparations." *Toxicon*, 26, No. 6 (1988), 525-534.
- [28] Chapman, D.S. "The Symptomatology, Pathology and the Treatment of the Bites of Venomous Snakes of Central and Southern Africa." In: Bucherl, W.; Buckley, E.E. and Deulofeu, V. (eds), *Venomous Animals and Their Venoms* (Vol. 1). New York and London: Academic Press, Vol. 1. 1968.

- [29] Corkill, N.L. "Snake Poisoning in the Sudan." In: Buckley, E.E. and Porges, N. (eds.) *Venoms*, American Association for the Advancement of Science. Washington: D.C., 1956.
- [30] Mendelsohn, H. "On the Biology of the Venomous Snakes of Israel." *Folia. Med.*, 21 (1962), 577.
- [31] Warrell, D.A.; Ormerod, L.D. and Davidson, N. "Bites by the Night Adder *Causus Maculatus* and Burrowing Viper Genus *Atractaspis* in Nigeria." *Am. J. Trop. Med. Hyg.*, 25 (1976), 517.
- [32] Efrati, P. "Viper Bites." *Family Physician*, 7 (1979), 94.
- [33] Pepeu, F. "Ulteriori Recerche Sugli Ofidi Velenosi Dell 'A.O.I." *Boll. Inst. Sieroter. Milan*, 18 (1939), 1.
- [34] Hassan, F.; El-Hawary, M.F.; Gazawi, A.; Anis, A. and Wanas, S. "Biochemical Properties of Egyptian *Cerastes* Venoms in Relation to Geographic Distribution." *Z. Ernährungswiss*, 19 (1980), 259-265.

حالة لدغ مميتة بثعبان أتراتاسبس يرصد لأول مرة في المنطقة الوسطى من المملكة العربية السعودية

محمد خالد السعدون ونصر محمد عبده

قسم علم الحيوان، كلية العلوم، جامعة الملك سعود، ص.ب ٢٤٥٥،

الرياض ١١٤٥١، المملكة العربية السعودية

(استلم في ٢٠ شعبان ١٤٠٩هـ، قبل للنشر في ١٢ ربيع الآخر ١٤١١هـ)

ملخص البحث. أدت حالة لدغ ثعبان مميتة من نوع أفعى الواحات الدافنة (اتراكتاسبس ماكروليبديوتا انقادنسيس هاس: ١٩٥٠م) إلى التعرف على هذه الأفعى لأول مرة في المنطقة الوسطى بالمملكة العربية السعودية.

وقد وُصِفَتْ خلال هذا البحث قياسات التعرف على هذه الأفعى، التوزيع الجغرافي الحالي، وكذلك تصنيفها في شبه الجزيرة العربية. كذلك نُوقِشت أعراض التسمم وعلاقتها مع تكوين السم وفعاليته حسب ما ذكر من تقارير بحثية سابقة.