

## **Histochemical Alterations in the Spleen of Rabbits Induced by Diclofenac Sodium (Voltaren)**

**\*Noory T. Taib and \*\*Bashir M. Jarrar**

*\*Department of Zoology, College of Science, King Saud University*

*\*\*Department of Clinical Laboratory Sciences,  
College of Medical Applied Sciences,  
Al-Jouf Branch, King Saud University*

(Received 6/11/1425H.; accepted for publication 13/8/1426H.)

**Abstract.** A total of 30 male rabbits were exposed to intraperitoneal injection with a daily dose of diclofenac sodium (1.5 mg/kg body weight) for 70 days to investigate the resultant histological and histochemical alterations in the splenic tissues. This regime of chronic exposure to subtoxic doses of diclofenac sodium has produced no histological alterations in the spleen but caused histochemical alterations mainly in the form of haemosiderosis with elevation in the activity of alkaline phosphatase, 5-nucleotidase and lactate dehydrogenase. The activity of mitochondrial adenosine triphosphatase was decreased while the activity of succinate dehydrogenase was not affected. The obtained results indicate that diclofenac sodium produces considerable histochemical alterations but little histological changes in the spleen.

**Keywords:** Diclofenac sodium, Spleen, Phosphatases, Dehydrogenases, Haemosiderosis.

### **Introduction**

Diclofenac sodium is probably one of the most common non-steroidal compounds with analgesic, anti-inflammatory, antirheumatic and antipyretic properties [1]. This drug has an inhibitory effect on prostaglandin synthesis and used as an initial therapy for inflammatory and degenerative rheumatic diseases as well as for pain conditions such as musculoskeletal and post-operative pains and acute attacks of gout and ureteric colic [2-3]. Diclofenac is metabolized in the liver to 4-hydroxy diclofenac and other hydroxylated forms after glucuronidation and sulfation before being eliminated principally via urinary and biliary excretions [4-5]. Diclofenac (daily dose of 1.5 mg/kg body weight) is claimed to be faster acting than Ibuprofen, longer acting than Paracetamol and as safe as Ibuprofen [6].

There are many side effects observed with the use of this drug. It is not recommended for (paediatric uses) while its overdosing is potentially toxic. Diclofenac sodium causes a rare but potentially fetal hepatotoxicity that may be associated with the formation of reactive metabolites and subsequent adverse hepatitis effects may arise in certain individuals [5, 7, 8]. Diclofenac provokes proliferation of bile duct, hepatocellular degeneration, non-specific hepatitis with portal and lobular activity. It also elevates markedly transaminases levels, decreases the glycogen content of the hepatocytes and impairs ATP synthesis by the mitochondria with futile consumption of reduced form of nicotinamide adenine dinucleotide phosphate (NADPH) [9-11].

Some studies have shown that diclofenac sodium accounts for the thickening of the glomerular basement membranes together with mild focal tubular necrosis and intraluminal secretions in the proximal convoluted tubules [6, 12]. Other less frequent effects on the urinary tissues include haematuria, proteinuria, interstitial nephritis, lipid peroxidation and papillary necrosis [6, 13, 14]. Diclofenac has been also reported to damage moderately the seminiferous tubules and to impair spermatogenesis [15].

There are limited studies on the histochemical alterations in the splenic tissues induced by chronic diclofenac sodium exposure. With this objective, a histological and histochemical study has been done on the spleen of adult rabbits killed at one week intervals up to 70 days of diclofenac sodium treatment.

## Material and Methods

### Experimental animals

A total of 30 adult male rabbits of three months age weighing 950-1000 gm obtained from Tahsin center, Riyadh, Saudi Arabia were used. Animals were kept in cages where each contained 2 animals.

### Experimental design

Following a period of acclimatization (7 days), diclofenac sodium (Proanalysis-Merck, Germany) was administered intraperitoneally at the rate of 1.5 mg/kg body weight. The control group (n = 10) received sterile distilled water via the same route and all animals were maintained on standard laboratory animal diet pellets *ad libitum*. Animals body weight was checked regularly and dosages based on the body weight of each animal were calculated. Three animals (two exposed and one control) were killed by decapitation of the neck at weekly intervals during 70 days of treatment with diclofenac sodium.

### Histological study

Fresh portions of the spleen from each rabbit were cut out rapidly, fixed in 10% neutral buffered formalin and Gender's fluid and then dehydrated with ascending grades of ethanol (70, 80, 90, 95 and 100%). Dehydration was then followed by clearing the tissue samples in 2 changes of chloroform before being impregnated with 2 changes of

melted paraffin wax, embedded and blocked out. Tissue sections (4-5  $\mu\text{m}$ ) were stained with haematoxylin-eosin, Mallory trichrome and prussian blue reaction according to the methods described by Pearse [16], Drury *et al.* [17], Bancroft and Stevens [18] and Kiernan [19] for the conventional histological procedure.

### Histochemical study

Portions of fresh spleen from each rabbit were cut out rapidly, frozen in liquid nitrogen and stored in air tight tubes at  $-80^{\circ}\text{C}$  until use. Cryostat sections (8-10  $\mu\text{m}$  in thickness) were cut at  $-25^{\circ}\text{C}$ . Unfixed fresh frozen cryostat sections were used for the histochemical characterization of the investigated phosphatases according to the following methods:

**Alkaline Phosphatase (ALPase):** The demonstration of ALPase was based on the modified medium described by Mayahara *et al.* [20]. The medium consisted of 10 mM  $\beta$ -glycerophosphate dissolved in 80 mM Tris-HCl buffer (pH 9.2) to which was added 3.9 mM magnesium chloride and 2.0 mM lead acetate. Sections were developed in yellow ammonium sulfide and mounted in glycerine jelly.

**5-nucleotidase (AMPase):** The reaction detecting AMPase was based on the metal salt method modified by Dawson *et al.* [21]. The medium consisted of 2 mM lead nitrate, 200  $\mu\text{M}$  5-adenosine monophosphate (5-AMP), 1 mM levamisole (alkaline phosphatase inhibitor), 1 mM manganese chloride, 0.1% gelatin, and 280 mM sucrose in tris maleate buffer (pH 7.4). The resultant lead phosphate was converted to lead sulfide by the addition of ammonium sulfide and mounted in glycerine jelly.

**Mitochondrial ATPase ( $\text{Mg}^{2+}$ -ATPase):** The activity of this enzyme was demonstrated by the method of Wachstein *et al.* [22]. The medium consisted of 0.83 mM adenosine triphosphate (disodium salt) dissolved in 0.2 M Tris-maleate buffer (pH 7.4), and 1 mM magnesium sulfate. Sections were post-treated in 2 mM lead nitrate, developed in yellow ammonium sulfide and mounted in glycerine jelly. The reaction of  $\text{Mg}^{2+}$ -ATPase was controlled by incubation set of sections in the above medium without magnesium sulfate.

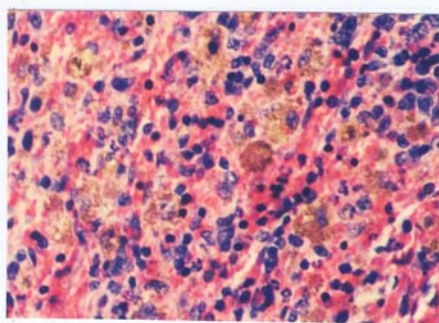
**Dehydrogenases:** Succinate and lactate dehydrogenases were histochemically demonstrated in the present study according to tetrazolium method [23, 24]. The final incubation medium for each enzyme consisted of the nitro blue tetrazolium (NBT) stock solution, the substrate solution and the employing co-enzyme. The NBT stock solution consisted of 2.5 ml NBT solution (4 mg/ml), 2.5 ml of 0.2 M Tris buffer (pH 7.4), 1 ml of 0.05 M magnesium chloride and 3 ml of distilled water. Potassium cyanide (100 mM) or sodium azide (100 mM), respiratory chain inhibitors of cytochrome systems, was added to the final incubating medium of the bound dehydrogenases. Phenazine methosulphate, an intermediate electron acceptor, was added to the incubating medium at the rate of 1 mg/ml of the medium.

### Results

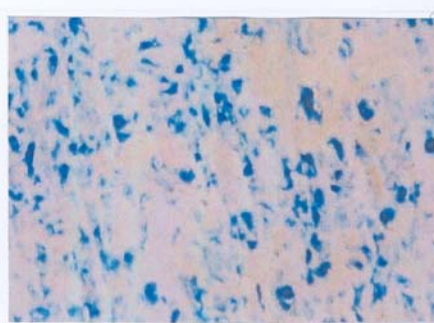
No mortality or clinical signs due to diclofenac sodium intoxication were observed for any of the treated rabbits over the entire experimentation period. In addition, no

increase in the ratio of spleen: body weight, in comparison to the control animals, or splenomegaly was recorded.

Compared with the respective control rabbits, diclofenac sodium produced no distinct histological splenic changes. No alterations were seen in the histological components of the red pulp, periarteriolar lymphoid sheath (white pulp), trabeculae and capsule of the spleen of treated rabbits in comparison with that of the control ones. A considerable increase in the number of resident macrophages in splenic cords of the treated rabbits was noticed (Fig. 1). More Prussian blue positive granules were observed in the cytoplasm of the macrophages of rabbits exposed to diclofenac sodium for 6 weeks compared with the untreated rabbits (Fig. 2). Haemosiderosis was not recognized in the periarteriolar lymphoid sheath components.



**Fig. 1.** Light micrograph of spleen showing an increase in the resident macrophage. Diclofenac treated rabbit. Eight weeks post-treatment. H&E. x270.



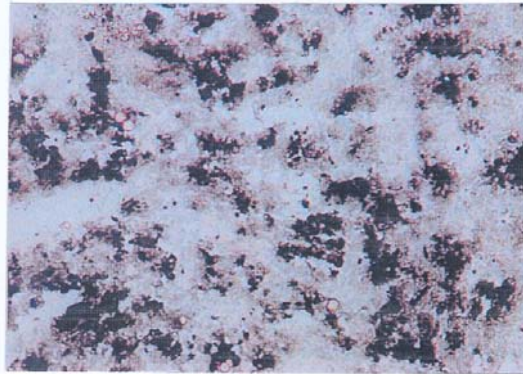
**Fig. 2.** Light micrograph of spleen showing extensive haemosiderosis. Diclofenac treated rabbit. Six weeks post-treatment. Prussian blue reaction. x450.

The histochemical characterization, distribution patterns and sites of activities of the investigated enzymes in the control and treated rabbits were as follows:

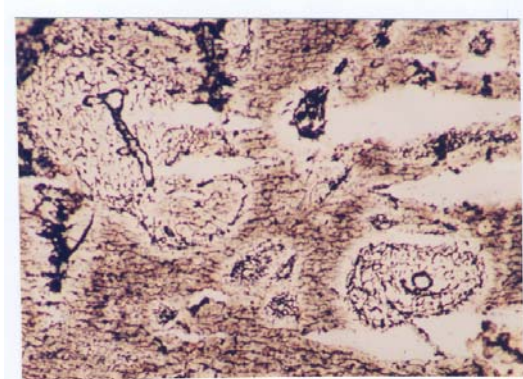
**Alkaline phosphatase:** In the control spleen, a strong activity of ALPase was seen in the foamy cells and macrophages of the red pulp while no activity for this enzyme was detected in the periarteriolar lymphoid sheaths. In the treated spleens, a significant increase in the activity of ALPase was observed in the foamy cells and macrophages as well (Fig. 3).

**5-nucleotidase (AMPase):** In the control spleens, the activity of AMPase was confined mainly to some components of the splenic cords. A considerable increase in the activity of AMPase was noticed in the splenic cords of the treated rabbits (Fig. 4).

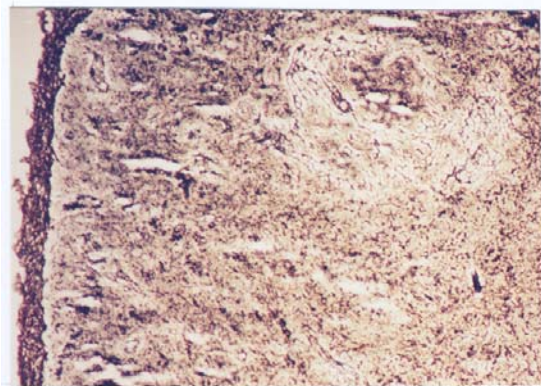
**Mitochondrial adenosine triphosphatase ( $Mg^{2+}$ -ATPase):** A moderate cytoplasmic activity of  $Mg$ -ATPase was recognized in the dendritic macrophages of the red pulp of the control spleens. The reaction of  $Mg^{2+}$ -ATPase in the spleens of diclofenac treated rabbits showed significant reduction in comparison with the respective control ones. The reduction in the activity was clear after five weeks of treatment (Fig. 5).



**Fig. 3.** Light micrograph of spleen showing significant activity of ALPase in the macrophages. Diclofenac treated rabbit. Ten weeks post-treatment. x450.



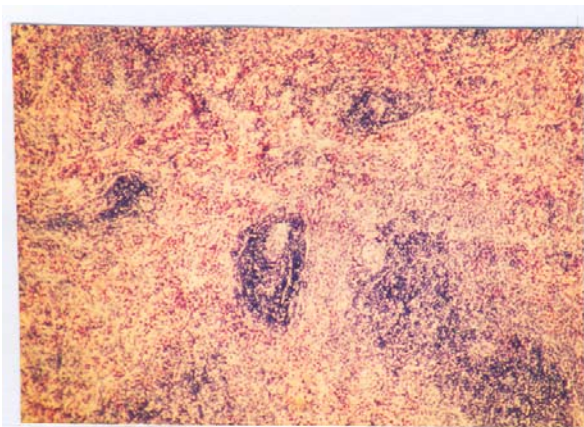
**Fig. 4.** Light micrograph of spleen showing considerable activity of 5-nucleotidase. Diclofenac treated rabbit. Metal salt method. Eight weeks post-treatment. x450.



**Fig. 5.** Light micrograph of spleen showing the activity of the mitochondrial ATPase. Diclofenac treated rabbit. Wachstein method. Five weeks post-treatment. x270.

**Succinate dehydrogenase (SDH):** In the control spleens, a considerable activity of SDH was demonstrated in the trabeculae, follicular arterioles of the white pulp, the penicillar arteries and to less extent in the splenic capsule. No significant change in the activity of SD in the spleen of diclofenac exposed rabbits was observed.

**Lactate dehydrogenase (LDH):** The spleens of the control rabbits showed a strong reaction for LDH in the trabeculae, splenic capsule and splenic arteries. A significant increase in the activity of LDH was detected in the spleen of rabbits exposed to diclofenac sodium in comparison to the untreated control animals (Fig. 6).



**Fig. 6.** Light micrograph of spleen showing the activity of the lactate dehydrogenase activity. Diclofenac treated rabbit. Tetrazolium method. Ten weeks post-treatment. x270.

### Discussion

The results of the present investigation showed that the subtoxic chronic diclofenac sodium exposure has no apparent effects on the splenic tissue. This might suggest that no deleterious action is exerted by diclofenac on the cellular components of the spleen. However, the drug under investigation increased the precipitation of haemosiderin in the red pulp of the treated rabbits. This might indicate an effect of diclofenac sodium on the haematopoiesis, probably in terms of increased destruction rate of erythrocytes. However, this effect is still to be elucidated.

The current results showed that diclofenac has no effect on the activity of succinate dehydrogenase but enhanced the activity of lactate dehydrogenase. Succinate dehydrogenase participates in the aerobic oxidation of carbohydrates in the citric acid cycle and is bounded to the inner mitochondrial membrane [25]. The stability of succinate dehydrogenase activity after diclofenac exposure possibly indicates that this drug does not impair mitochondrial functions and carbohydrates oxidation in the aerobic metabolic processes especially the electron transport. This finding may also indicate that there is no effect on the oxidative phosphorylation of the cellular

components of the splenic tissues. The increase in the activity of lactate dehydrogenase which plays an important role in the intermediary metabolism as a link between amino acid metabolism and the citric acid cycle where it converts lactate into pyruvate [25] might indicate a role for diclofenac in increasing this process.

The results of the present work showed that diclofenac sodium enhanced the activity of alkaline phosphatase and 5-nucleotidase but decreased the activity of mitochondrial adenosine triphosphatase. This finding suggests increased transmembrane transport of diclofenac where alkaline phosphatase is involved in the absorption and transportation across these membranes [26]. On the other hand, alkaline phosphatase is a meta-enzyme and contains zinc as an integral part [27]. The non-specific increase in the activity of alkaline phosphatase by diclofenac exposure may be a result of the incorporation of the drug in the place of zinc atoms leading to an increase in the activity of this enzyme. 5-nucleotidase is a dephosphorylating enzyme related to cyclic AMP and involved in the catabolism of nuclear material in disintegrating cells and specifically dephosphorylates 5-monucleotides [28]. Hence, the present results might suggest a possible role of this enzyme in the catabolism of nucleic acids in the cells disintegrated by diclofenac effect. Mitochondrial adenosine triphosphatase is inhibited by any substance that blocks sulfohydryl (SH) group. The decrease in the activity of mitochondrial adenosine triphosphatase due to diclofenac exposure may be resulted from its interaction with the sulfohydryl groups and the oxidative phosphorylation of the cells.

Alterations in the activity of some splenic phosphatases and dehydrogenases due to diclofenac exposure were demonstrated in the present study. This might lead us to conclude that the changes in the activity of these enzymes might represent adaptive responses to the changes in the catabolism of the splenic cells or indicate partial impairments of their functions induced by diclofenac.

### References

- [1] Miwa, L.J.; Jones, J.K.; Pathiyal, A. and Hatoum, A. "Value of Epidemiological Studies in Determining the True Incidence of Adverse Events. The Non-steroidal Anti-inflammatory Drug Story." *Arch. Intern. Med.*, 157, No. 18 (1997), 2129-2136.
- [2] Morgan, G. "Beneficial Effects of NSAIDS in the Gastrointestinal Tract." *Eur. J. Gastroenterol. Hepatol.*, 11 (1999), 393-400.
- [3] Perttunen, K.; Nilsson, E. and Kalso, E. "I.V. Diclofenac Ketorolac for Pain after Thoracoscopic Surgery." *Br. J. Anaesth.*, 82, No. 2 (1999), 221-227.
- [4] Mascher, H. "Comparative Metabolism of the Non-steroidal Anti-inflammatory Drug, Diclofenac, in the Rat, Monkey and Human." *Drug Metab. Dispos.*, 24 (1996), 969-997.
- [5] Tang, W.; Stearns, R. and Banndiera, S.M. "Studies on Cytochrome P-450 Mediated Bioactivation of Diclofenac in Rats and Human Hepatocytes: Identification of Glutathione Conjugated Metabolites." *Drug Metabol. Dispos.*, 27, No. 3 (1999), 365-372.
- [6] Farag, M.M.; Mikhail, M.; Shehata, R.; Abdel-Maguid, E. and Abdel-Tawab, S. "Assessment of Gentamicin-induced Nephrotoxicity in Rats Treated with Low Doses of Ibuprofen and Diclofenac Sodium." *Clin. Sci. (Coch)*, 91, No. 2 (1996), 187-191.
- [7] Ouellette, G.S.; Slitzky, B.E.; Gates, J.A.; Lagarde, S. and West, A.B. "Reversible Hepatitis Associated with Diclofenac." *J. Clin. Gastroenterol.*, 13, No. 2 (1991), 205-210.
- [8] Bhogaraju, A.; Nazeer, S.; Al-Baghdadi, Y.; Rahman, M.; Wrestler, F. and Patel, N. "Diclofenac-associated Hepatitis." *South Med. J.*, 92, No. 7 (1999), 711-713.

- [9] Bort, H.; Huber, R.; Steinijs, V.W.; Koch, H.J.; Wurst, W. and Mascher, H. "Comparative Metabolism of the Non-steroidal Anti-inflammatory Drug, Diclofenac, in the Rat, Monkey and Human." *Drug Metab. Dispos.*, 24, No. 9 (1991), 969-975.
- [10] Bort, R.; Ponsoda, X.; Jover, R.; Gomez-Lechon, M.J. and Castell, J.V. "Diclofenac Toxicity to Hepatocytes: A Role for Drug Metabolism in Cell Toxicity." *J. Pharmacol. Exp. Ther.*, 288, No. 1 (1999), 65-72.
- [11] Gabry, M.S.; Elewa, F.H. and Ibrahim, M.A. "Histochemical Evaluation of the Hepatic and Intestinal Damage Associated with Diclofenac Administration: A Light and Electron Microscopic Study." *J. Egypt Ger. Soc. Zool. Histology and Histochemistry*, 27 (1999), 117-153.
- [12] Taib, N.T.; Jarrar, B.M. and Mubarak, M.M. "Ultrastructural Alterations in Renal Tissues of Rabbits Induced by Diclofenac Sodium (Voltaren)." *Saudi Med. J.*, 25, No. 10 (2004), 1360-1365.
- [13] Bougie, D.; Johnson, S.T.; Weitekamp, L.A. and Aster, R.H. "Sensitivity to a Metabolite of Diclofenac as a Cause of Acute Immune Hemolytic Anemia." *Blood*, 90, No. 1(1997), 407-413.
- [14] Kim, H.; Yu, M.; Lin, Y.; Cousins, M.J.; Eckstein, R. P. and Jordan, V. "Renal Dysfunction Associated with the Preoperative Use of Diclofenac." *Anesth. Analg.*, 89 (1999), 999-1005.
- [15] Steitica, F.M.; Ali, S.S. and Muhamed, S.A. "Morphological Changes of the Mouse Testes under the Influence of Diclofenac Sodium (Voltaren): A Light and Electron Microscopic Study." *Egypt. J. Anat.*, 17, No. 2 (1994), 387-407.
- [16] Pearse, A.E. *Histochemistry. Theoretical and Applied: Analytical Technology*. 4<sup>th</sup> ed., Vol. 2, Edinburgh: Churchill-Livingstone, 1985.
- [17] Drury, R.A.; Wallington, B.D. and Cameron, S.R. *Carleton's Histological Techniques*. 5<sup>th</sup> ed., New York: Oxford University Press, 1983.
- [18] Bancroft, J. D. and Stevens, A. *Theory and Practice of Histological Techniques*. 2<sup>nd</sup> ed., Edinburgh: Churchill Livingstone, 1986.
- [19] Kiernan, J.H. *Histological and Histochemical Method: Theory and Practice*. 2<sup>nd</sup> ed., Oxford: Pergamon Press, 1989.
- [20] Mayahara, H.; Hirano, H.; Saito, T. and Orgawa, K. "The New Lead Citrate Method for the Ultracytochemical Demonstration of Non-specific Alkaline Phosphatase (Orthophosphoric Monoster Phosphohydrolase)." *Histochemie.*, 11 (1967), 88.
- [21] Dawson, T. P.; Gandhi, R.; Hir, M.L. and Kaissling, B. "Ecto-5-nucleotidase: Localization in Rat Kidney by Light Microscopic Histochemical and Immunohistochemical Methods." *J. Histochem. Cytochem.*, 37 (1998), 39-47.
- [22] Wachstein, M.; Bradshaw, M. and Ortiz, J.M. "Histochemical Demonstration of Mitochondrial Adenosine Triphosphatase Activity in Tissue Solutions." *J. Histochem. Cytochem.*, 10 (1962), 63-74.
- [23] Lojda, Z.; Gossrau, R. and Schiebler, T. H. *Enzyme Histochemistry. A Laboratory Manual*. Berlin: Springer-Verlag, 1979.
- [24] Stoward, P.J. and Van Noorden, C. F. "Histochemical Methods for Dehydrogenases." In: P.J. Stoward and A.G.E. Pearse (Eds.), *Histochemistry Theoretical and Applied*. 4<sup>th</sup> ed., Vol. 3, Edinburgh: Churchill Livingstone, 1991.
- [25] Al-Rehaimi, A.A.; Al-Ali, A.K.; Mutairy, A.R. and Dissanayake, A.S. "A Comparative Study of Enzyme Profile of Camel (*Camelus dromedaries*) Hump and Sheep (*Ovis aries*) Tail Tissues." *Comparative Biochem. Physiol.*, 93 (1989), 857-858.
- [26] Sandhir, R. and Gill, K. "Effect of Lead on Lipid Peroxidation in Liver of Rat." *Biological Trace Element Research*, 48 (1995), 91-97.
- [27] Boyer, D. P. *The Enzymes*. 3<sup>rd</sup> ed., New York: Academic Press, 1971.
- [28] Hardonk, M. J. "5-nucleotidase. I. Distribution of 5-nucleotidase in Tissues of Rat and Mouse." *Histochemie.*, 12 (1968), 1-17.

( )

<sup>1</sup>قسم علم الحيوان، كلية العلوم بالرياض، جامعة الملك سعود  
قسم علوم المختبرات الطبية، كلية العلوم الطبية التطبيقية بالجبوف، جامعة الملك سعود

(قدم للنشر في ١١/٦/١٤٢٥هـ؛ وقبل للنشر في ١٣/٨/١٤٢٦هـ)

**ملخص البحث.** استعمل في هذا البحث ٣٠ أرنباً بالغاً من أجل تحري التغيرات الكيميائية النسيجية التي يحدثها عقار ديكلوفناك الصوديوم المعروف بالفولتارين. تم إعطاء الجرعات عن طريق الحقن بتجويف البطن لمدة ٧٠ يوماً متتالياً بمعدل ١.٥ ملجم/كجم من وزن الجسم. أظهرت نتائج هذا البحث أن التعرض لجرعات مزمنة تحت عتبة السمية من عقار ديكلوفناك الصوديوم لا تتسبب بإحداث تغيرات نسيجية بالطحال لكنها تحدث به تغيرات كيميائية نسيجية تتمثل بالأساس بترسيب لصبغيات الهيموسدرن وزيادة في وتيرة البلعمة الخلوية، إضافة إلى ارتفاع في نشاط كل من الفوسفاتاز القاعدي ونيكلوتيداز - ٥ ونازع هيدروجين اللاكتات بينما تتسبب بالمقابل في خفض نشاط أدونسين ثلاثي الفوسفاتاز ولم يحدث أي تغير على الإطلاق في نشاط نازع هيدروجين السكسنت. يمكن الاستنتاج من نتائج هذا البحث أن عقار ديكلوفناك الصوديوم يحدث تغيرات كيميائية نسيجية بالطحال بينما التغيرات النسيجية التي يحدثها جد محدودة.

