

***Trichosomoides crassicauda* Infection in Wistar Rats**

***Fatima Al-Humaid, **O.M. Mahmoud, E.M. Haroun, M. Magzoub,
A.A. Al-Qarawi, O.H Omer and A. Sulman**

**Girls' College, Buraydah, Gassim and **Department of Veterinary Medicine,
King Saud University, P. O. Box 1482, Buraidah, Gassim, Saudi Arabia*

(Received 6/8/1418; accepted for publication 7/2 /1419)

Abstract. Natural infection of locally bred Wistar rats with *Trichosomoides crassicauda* produced hypertrophic changes in the transitional epithelium of the urinary bladder and renal pelvis and suppurative pneumonia. Urinary bladder infection was not associated with clinical signs but mortalities resulted from bronchopneumonia produced by the migrating juvenile worms. Only remnants of worm bodies were seen in lung tissue. There were no macroscopic urinary system lesions, but histopathological examination showed presence of the juvenile parasites in the subepithelial tissue of the urinary bladder and renal pelvis with minimal tissue reaction. There were no lesions in the stomach, spleen, liver or kidneys to indicate possible migration of the juvenile worms through them. Juvenile worms were also seen in the seminiferous tubules of the testis which showed severe degeneration.

Key words: *Trichosomoides* infection, Wistar rats, *Trichosomoides crassicauda*.

Introduction

Urinary destosomiasis in laboratory rats is caused by the small nematode, *Trichosomoides crassicauda* (females : 10-19 mm; males: 1-3.5 mm [1], which infects the urinary bladder and renal pelvis causing hypertrophic changes and mild inflammation without apparent clinical signs [2]. The parasite has also been incriminated in causing calculi and tumors of the urinary bladder [3;4]. The parasite eggs pass with the urine [5], contaminate food and water and are ingested by the next host where they hatch in the stomach. The emerging larvae migrate freely to the lungs then pass through the blood stream to the kidneys from which they descend to the ureters to lodge in the urinary bladder [6]. There is no previous report describing the presence of this parasite in the Kingdom of Saudi Arabia. In this paper, we describe a fatal pneumonia in a laboratory

rat colony due to *Trichosomoides crassicauda* infection, as well as a first record of its existence in the reproductive organs.

Materials and Methods

Twenty-two Wistar rats, of both sexes, from a laboratory rat colony, died of respiratory infection and were subjected to a detailed postmortem examination. Six clinically healthy rats were killed with ether, and necropsied. Samples were taken from lungs, liver, spleen, kidneys, intestine and stomach. Urinary bladders were carefully dissected out, put into a petri-dish containing distilled water and sliced open with a scalpel to obtain worms and eggs. They were then fixed with other tissue samples in 10 % formol saline for routine histopathological processing. Paraffin sections were stained with haematoxylin and eosin (H&E). No microbiological tests were made on the dead rats' tissues.

Results and Discussion

Juvenile and adult worms as well as embryonated eggs of *T. crassicauda* were found in urinary bladder washes (Fig. 1). Embryonated eggs were also seen in worms *in utero*. Lung lesions were found in all rats that died of the disease but were not observed in clinically healthy ones. In addition to the lungs, lesions were found in the urinary bladder, renal pelvis and testes. In the lungs, lesions were those associated with suppurative bronchopneumonia.

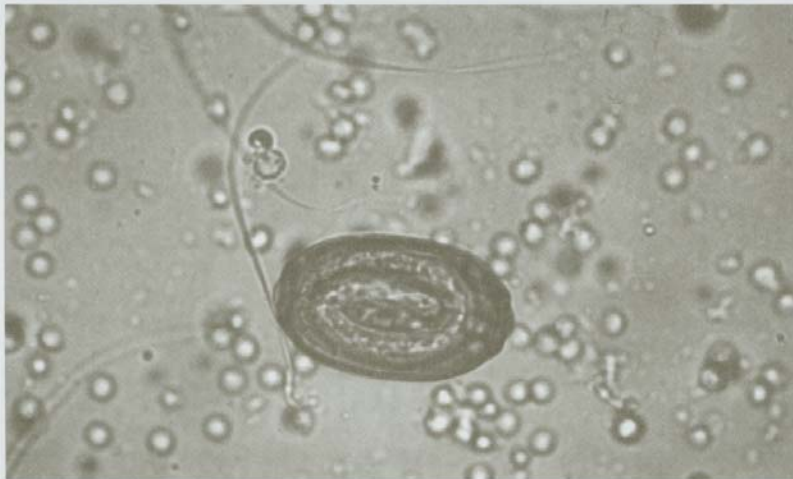


Fig. 1. Embryonated eggs in urinary bladder wash.

Bronchioles were filled with inflammatory cells, mainly neutrophils and eosinophils, and remnants of dead worms were observed (Fig. 2). The lesion in the urinary system was hypertrophy of the transitional epithelium of the urinary bladder and renal pelvis, under which juvenile worms were seen, but in many instances the parasites were seen lodged subepithelially without provoking tissue reaction (Fig. 3). The parasite did not produce inflammation in any part of the urinary system.

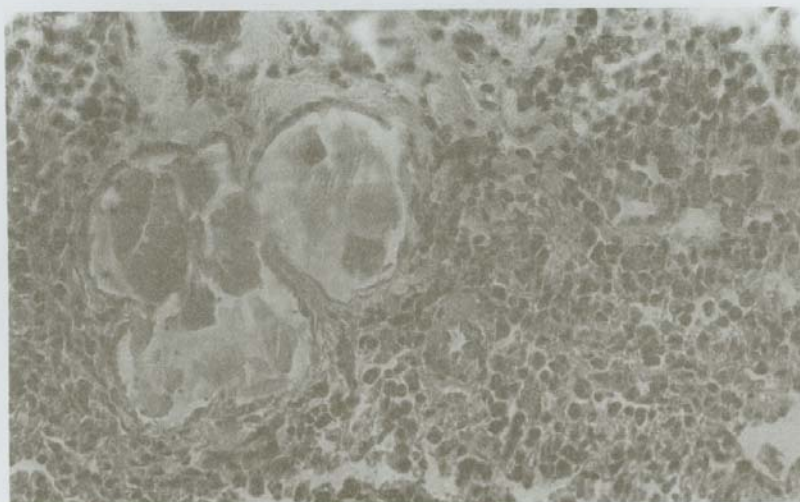


Fig. 2. Bronchopneumonia and remnants of worms in lung tissue, H&E x 250.

Juvenile worms were also found in the seminiferous tubules of the testis, which showed severe degeneration (Fig. 4). Histological examinations of the liver, spleen, stomach and intestine revealed no lesions.

With the exception of testicular infection, the lesions produced by *T. crassicauda* in the urinary bladder, renal pelvis and lungs were similar to those reported elsewhere [2;7-9]. The infection of rats with *T. crassicauda* is thought to be through ingestion of eggs with food and water [1, p.342]. The eggs hatch in the stomach giving larvae, which migrate freely to the lungs and through the blood to the kidneys where they travel down stream to the urinary bladder where they reach maturity. Al-Zubaidy *et al.* [2] reported that rats as young as 14 - 15 weeks were infected with the parasite and suggested that infection could be neonatal or prior to weaning. Vertical transmission of infection from parents to offspring, without *in utero* transmission, was reported by Wisbroth and Scher [10].



Fig. 3. Juvenile worms under normal epithelium of the urinary bladder provoking no tissue reaction. (H&E x 250).

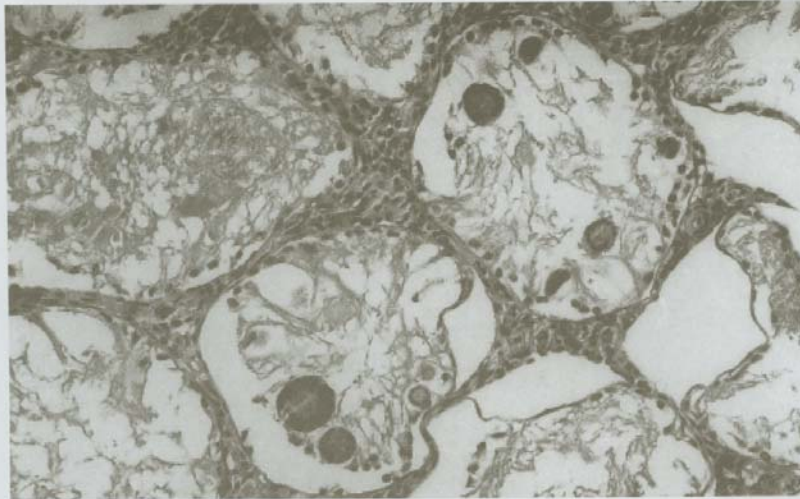

Fig. 4. Juvenile worms in degenerate seminiferous tubules of the testis. H&E x 250.

There were no hemorrhages in the examined lungs, which showed that no penetration of blood vessels by the parasite had taken place. Only remnants of dead worms were seen in the inflamed lungs and no intact worm bodies were seen. Parasites that migrate through the blood stream usually produce severe lesions in various organs especially the liver and are likely to cause inflammation at the site of their exit from tissue to blood and *vice versa*. In the present investigation, no such lesions were seen in the kidneys.

References

- [1] Soulsby, E. J. L. *Helminths, Arthropods and Protozoa of Domesticated Animals*. London: Bailliere Tindall, 1982.
- [2] Zubaidy, A. J. and Majeed, S. K. "Pathology of the Nematode *Trichosomoides crassicauda* in the Urinary Bladder of Laboratory Rats." *Laboratory Animals*, 15 (1981), 381-384.
- [3] Chapman, W. H. "The Incidence of the Nematode *Trichosomoides crassicauda* in the Bladder of Laboratory Rrats." *Investigative Urology*, 2 (1964), 52-57.
- [4] Smith, V.S. "Are Vesicle Calculi Associated with *Trichosomoides crassicauda*, the Common Bladder Nematode of Rats?" *Journal of Parasitology*, 32 (1946), 142-149.
- [5] Cornich, J., Vanderwee, A. M., Findon, G. and Miller, T. E. "Reliable Diagnosis of *Trichosomoides crassicauda* in the Urinary Bladder of the Rat." *Laboratory Animals*, 22 (1988), 162-165.
- [6] Whal, D.V. and Chapman, W.H. "The Application of Data on the Survival of *Trichosomoides crassicauda* to the Control of This Bladder Parasite in Laboratory Rat-colonies." *Laboratory Animal Care*, 17 (1967), 386-390.

- [7] Ahlqvist, J. and Kohonen, J. "On the Graduated Cells of the Urinary Tract in Rats Infected with *Trichosomoides crassicauda*." *Acta Pathologica et Microbiologica Scandinavica*, 46 (1959), 313-319.
- [8] Bone, J. P. and Harr, J. R. "Trichosomoides crassicauda Infection in Laboratory Rats." *Laboratory Animal Care*, 17 (1967), 321-326.
- [9] Bell, D.B. "Disease in Caesarian-derived Albino Rat Colony and in Conventional Colony." *Laboratory Animals*, 2 (1968), 1-17.
- [10] Wisbroth, S.H. and Scher, S. "Trichosomoides crassicauda Infection of a Commercial Rat Breeding Colony. 1. Observation on Life Cycle and Propagation." *Laboratory Animal Sciences*, 21 (1971), 54-61.

**الإصابة بطفيلي *Trichosomoides crassicauda*
في الجرذان المخبرية في المملكة العربية السعودية**

*فاطمة الحميد، أسامة محمد محمود، الطاهر محمد هارون، محمد مجذوب،
علي عبد الله القرعاوي، أسامة حسن عمر، وعبدالله سلمان
*كلية النبات، بريدة القصيم، وقسم الطب البيطري، كلية الزراعة والطب البيطري،
جامعة الملك سعود، فرع القصيم، بريدة، القصيم

(قدم هذا البحث للنشر في ١٤١٨/٨/٦ هـ؛ وقبل للنشر في ١٤١٩/٢/٧ هـ)

ملخص البحث. أدت الإصابة بطفيل *Trichosomoides crassicauda* في جرذان ويستر Wistar rats إلى تضخم في الطبقة الطلائية الانتقالية للمثانة والحوض الكلوي مع التهاب رئوي قيحي. ولم تكن إصابة المثانة مرتبطة بعلامات إكلينيكية، ولكن الوفيات نتجت عن التهاب رئوي بسبب هجرة الديدان الصغيرة في الرئة. وقد لوحظت بقايا الديدان في نسيج الرئة. ولم تظهر آفات عيانية في الجهاز البولي، ولكن الفحص المجهرى بين وجود يرقات الديدان في النسيج تحت الطلائي للمثانة والحوض الكلوي. كذلك وجدت اليرقات في نسيج الخصية التي ظهر بها تنكس في النبيبات ناقلة المنى.